

# Intestinal Amoebiasis: Delayed-type Hypersensitivity Response in Mice

Prabir K. Ghosh\*, Sadhna Gupta, and Librado Ortiz-Ortiz

Department of Immunology, Instituto de Investigaciones Biomedicas, Universidad Nacional Autonoma de Mexico, 04510 Mexico D.F.

## ABSTRACT

Delayed-type hypersensitive (DTH) response was evaluated in C3H/HeJ mice intestinally infected with *Entamoeba histolytica*. Infected and non-infected control mice were challenged with amoebic antigen on day 5, 10, 15, 20, 25, 30, 40, 50, and 60 post-infection. Maximum footpad swelling was observed after 24 hours of the challenge. The *E. histolytica*-infected mice exhibited a DTH response on day 5, 15, 20, 25, 40, and 60 post-infection. However, on day 10, 30, and 50, such response was similar to that of the non-infected control mice. The mice developed an evident DTH response late in the course of infection (25 days post-infection). The infected mice did not show any alteration to their DTH response against heterologous unrelated antigen (sheep red blood cells), suggesting that cellular anergy was antigen-specific.

**Key words:** *Entamoeba histolytica*; Amoebiasis; Disease models, Animal

## INTRODUCTION

*Entamoeba histolytica*-associated infection is a public health problem in many developing countries, where it is responsible for severe morbidity and mortality (1). It is believed that delayed-type hypersensitivity (DTH) or migration inhibition factor (MIF) studies are an expression of cell-mediated immunity (CMI) (2). Initiation of a DTH response depends on recruitment from the blood stream of specifically sensitized T-cells. Re-exposure to the same antigen causes these lymphocytes to produce cytokines, some of which are able to attract non-specifically and activate the mononuclear cells from the circulation. Thereafter, some of them transform morphologically into macrophages, while others remain morphologically indistinguishable from blood monocytes, giving rise to swelling causing non-specific tissue destruction either directly or by releasing inflammatory cytokines (3).

Measurement of DTH at a peripheral site, such as footpad or ear, provides a means of quantifying the degree of sensitization to a given antigen (3-5). Several

All correspondence and reprint requests should be addressed to (\*present address): Dr. Prabir K. Ghosh  
Department of Immunology  
Kothari Medical Centre and Research Institute  
8/3, Alipore Road, Calcutta 700 027  
INDIA  
Fax: +91 33-4567045

studies on DTH were carried out by dermal reactions to *E. histolytica* antigen in humans (6-10) and in animals (5,11). It is known that DTH reactions remain for a long time after recovery from the amoebic disease (2).

Since there is a lack of information regarding host immune reactivity during the course of intestinal amoebiasis, we evaluated the pattern of DTH response in C3H/HeJ mice over a period of time. We used a mouse model of intestinal amoebiasis, comparable to the human disease (12). The cellular immune response to heterologous antigen was also investigated.

## METHODS AND MATERIALS

### Preparation of *E. histolytica* antigen

***E. histolytica* strain HM1:** IMSS was grown axenically in TYI-S-33 medium (13). Amoebae were harvested as described elsewhere (14), and were lysed by 3 cycles of freeze-thawing. Protein concentrations were determined following the method of Bradford (15), using bovine serum albumin (BSA) as a standard. Amoebic antigens were kept in aliquots at -70 °C until used.

### Monoxenic cultures of *E. histolytica*

**Axenic *E. histolytica* strain HM1:** IMSS was maintained in Robinson's medium associated with *Escherichia coli* (16) as described before (12).

### Animals

Mice strain C3H/HeJ of 3-5 weeks of age, weighing 20-25 g, were used in the experiment. Mice colonies were maintained at the Instituto de Investigaciones Biomedicas, Universidad Nacional Autonoma de Mexico, Mexico D.F. The animals were free of parasites as evidenced by repeated stool examination. They were given sterile Purina pellets (Purina de Mexico, S.A. de C.V.) and water ad libitum.

### Intracaecal inoculation of mice

Mice were inoculated with monoxenic *E. histolytica* culture as described before (12). Briefly, amoebae were inoculated by laparotomy under light ether anesthesia, and then about  $5 \times 10^5$  trophozoites in 0.15 mL of culture medium were inoculated intracaecally. Non-infected control mice were inoculated in the same manner with Robinson's culture medium containing *E. coli*, but free from *E. histolytica*.

### Footpad test to *E. histolytica* antigens

DTH responses against *E. histolytica* antigens were evaluated during the evolution of the infectious process by the footpad test on day 5, 10, 15, 20, 25, 30, 40, 50, and 60 post-infection. Mice were injected subcutaneously with 1  $\mu$ g of *E. histolytica* antigen in 30  $\mu$ L phosphate-buffered saline (PBS, pH 7.2) into left hind footpad and an equivalent volume of PBS into the right hind footpad using a 27-gauge needle. Footpad swelling was evaluated, measuring the footpad thickness just before and after 24 and 48 hours of the injection of antigen using a dial caliper (Precision 0.01 mm, Mitutoyo Tokyo, Japan) and expressed as the difference in footpad thickness (in mm). Optimal antigen concentrations for DTH assays were determined after preliminary experiments. Mice once used in the experiment were sacrificed, and caecal lesions were scored according to Neal (17). Briefly, (i) *Caecal wall*: Normal, 0; Slight thickening, 1; Marked local thickening and contraction, 2; Extensive thickening and contraction, 3; Caecum shapeless, extensive ulceration with abscess formation, 4; (ii) *Caecal contents*: Normal, 0; Slightly less solid than normal, 1; Slightly mucoid, 2; Mucoid, some solid matter present, 3; No solid matter, white or yellow mucus only, 4. In each experiment, four mice per group were used, and the experiments were repeated three times.

### DTH reactions to unrelated antigens

DTH reactions to sheep red blood cells (SRBC) were evaluated in C3H/HeJ mice on day 5, 10, 25, 30, 40, and 50 post-infection. Three different groups were selected: Group I: Non-infected control mice, received only *E. coli*, were injected intravenously with  $5 \times 10^5$  SRBC in 0.3 mL of PBS. Four days later, mice were

challenged in left hind footpad with  $5 \times 10^8$  SRBC suspended in 30  $\mu$ L of PBS and an equivalent volume of PBS into right hind footpad. Footpad swelling was measured immediately before and 24 hours later. Group II: *E. histolytica*-infected mice were injected intravenously with  $5 \times 10^5$  SRBC in 0.3 mL of PBS, and four days later, mice were challenged as described above. Group III: Normal mice, not injected with SRBC, were challenged in left hind footpad with  $5 \times 10^8$  SRBC in 30  $\mu$ L of PBS and an equivalent volume of PBS in right hind footpad as described above. In each experiment, four mice per group were used, and the experiments were repeated three times.

### Histological studies

Infected and non-infected control mice, challenged with amoebic antigen, were sacrificed for histological analysis to ascertain the presence of amoebic infection. The caecum was removed and fixed in 10% formalin in PBS (pH 7.2). The tissues were dehydrated and embedded in paraffin and sectioned at 4  $\mu$ m. The sections were stained with Harris' haematoxylin and eosin (18).

### Statistical analysis

All results were expressed as the mean  $\pm$  standard deviation ( $sn-1$ ) of three separate experiments. Comparisons between groups were made using Student's two-tailed *t*-test. *p* values  $<0.05$  were considered significant.

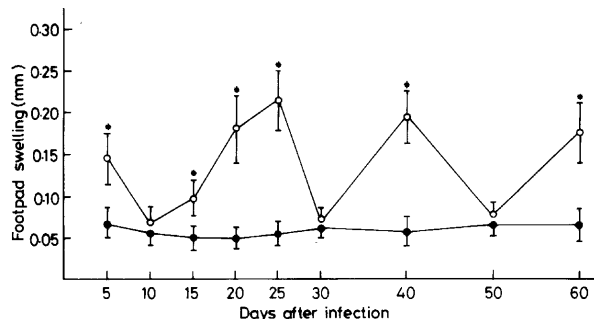
## RESULTS

### DTH response in intestinally-infected mice

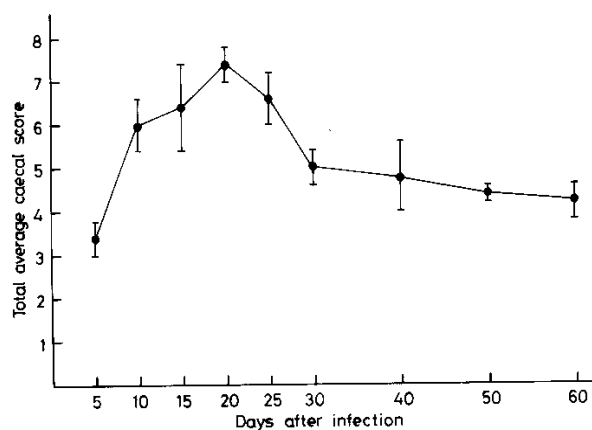
The *E. histolytica*-infected and non-infected control mice were challenged with *E. histolytica* antigen on day 5, 10, 15, 20, 25, 30, 40, 50, and 60 post-infection, and the DTH response was measured as the difference in footpad swelling before and after the challenge and expressed in mm. The non-infected control mice were injected with *E. coli* flora that was a component of the monoxenic media but free from *E. histolytica*. The infected mice showed strong footpad swelling 24 hours after the challenge, and the data are shown in Fig. 1. However, after 48 hours of challenge, a weak footpad swelling was observed (data not shown). The *E. histolytica*-infected mice showed a significant increase in footpad swelling on day 5, 15, 20, 25, 40, and 60 post-infection compared to the non-infected control mice ( $p < 0.05$ ). However, on day 10, 30, and 50 post-infection, the footpad swellings were found to be similar to those of the non-infected control mice.

### Analysis of *E. histolytica* infection in C3H/HeJ mice

The *E. histolytica*-infected and non-infected control mice challenged with amoebic antigen at respective time

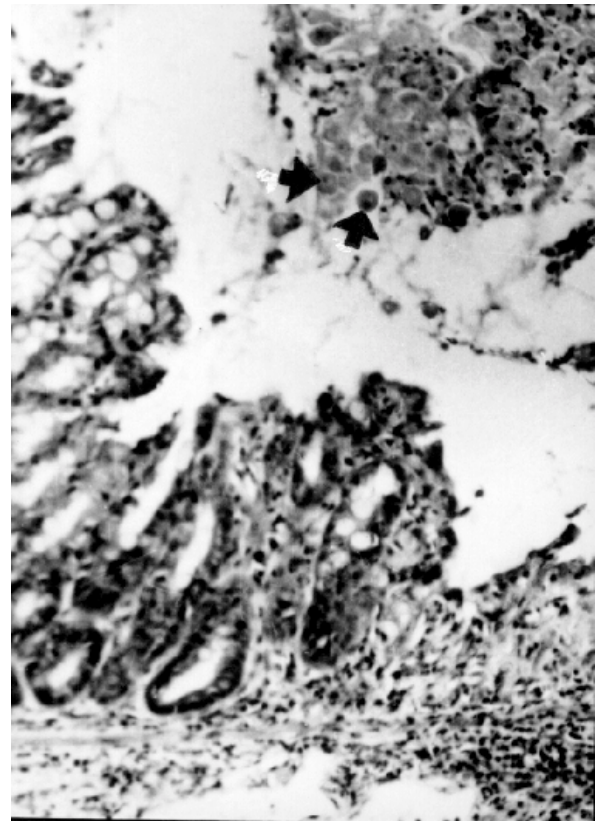


**Fig. 1.** DTH responses elicited either intracaecally infected with *E. histolytica* (○) or from non-infected control mice (●). Results are reported as mean values of 4 mice  $\pm$  *sn*-1 of three separate experiments. In each experiment, 4 mice each from the infected and the non-infected control groups were used. (★)  $p < 0.05$  (experimental vs control groups)



**Fig. 2.** Course of *E. histolytica* infection in intracaecally inoculated mice C3H/HeJ. Data represent mean values of 4 mice  $\pm$  *sn*-1 of three separate experiments

intervals were sacrificed to evaluate caecal lesions as described by Neal (17). The total average gradations of caecal lesions are presented in Fig. 2. From day 5 to day 15 post-infection, the caecum of mice showed contractions in the caecal wall, and the caecal contents were replaced by whitish or yellowish mucoïd material. These changes were observed extensively on day 20 post-infection, which decreased later (25-60 days post-infection). The presence of *E. histolytica* trophozoites was recognized by their large size and pseudopodial movements in the caecal contents of all the infected mice. The presence of amoebae was also confirmed by inoculating a caecum fragment of the infected mice separately in Robinson's medium. The growth of trophozoites was observed after 48-72 hours of culture. Histopathological studies of the caecal lesions showed erosion of the surface epithelium and gland destruction associated with an inflammatory response in all the sacrificed mice. *E. histolytica* trophozoites were seen in



**Fig. 3.** Section of the caecum of C3H/HeJ mouse, with amoebic trophozoites on the mucosal tissues of the intestine observed at day 5 post-infection. Amoebae indicated by arrows (H&E, x200).

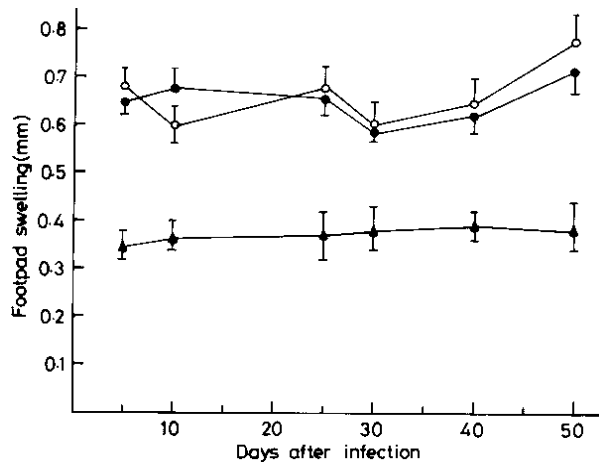
large numbers immersed in a sheet of mucus usually present overlying the eroded mucosa in all the mice. The non-infected control mice did not show any pathological changes (Fig. 3).

#### DTH response to SRBC

The DTH response to SRBC was assayed on day 5, 10, 25, 30, 40, and 50 post-infection. The SRBC-sensitized and footpad-challenged non-infected control mice showed significantly higher footpad swelling compared to that of the challenged but non-sensitized mice ( $p < 0.001$ ). The *E. histolytica*-infected mice, sensitized with SRBC and footpad challenged, displayed DTH responses similar to those of the sensitized non-infected control mice (Fig. 4).

#### DISCUSSION

The association of cellular immune depression during the amoebic disease in patients with *E. histolytica* as reflected by skin reactions was noted by several investigators (7,9,10). Landa *et al.* (10) stated that this depression was not due to the lack of T-lymphocytes



**Fig. 4.** DTH responses against SRBC in mice infected with *E. histolytica* and in non-infected control animals. Three different groups were tested. Results are reported as mean values of 4 mice  $\pm$  sn-1 of three separate experiments. Group I. Sensitized and footpad-challenged non-infected control mice (○); Group II. Sensitized and footpad-challenged *E. histolytica*-infected mice (●); Group III. Normal mice only footpad challenged with SRBC (▲).

but probably due to an inhibitory factor. Ortiz-Ortiz *et al.* (19) reported a similar period of anergy in experimentally-infected hamsters. These observations suggest that the cellular immune response is one of the most important resistance mechanisms operating in *E. histolytica*-infected hosts (9). Till date, no suitable experimental model is available. Mouse is an ideal host to study the mechanisms of host resistance to infection, since it is highly amenable to experimental manipulation, and its immunological system has been well detailed. Thus, the advantage has been taken of the murine model of intestinal amoebiasis developed in our laboratory to study the DTH responsiveness of the host to *E. histolytica* antigen from day 5 to day 60 post-infection.

Footpad swelling was observed to be cyclic in the *E. histolytica*-infected mice challenged with the amoebic antigen. The post-infection response was high on day 5 ( $p < 0.001$ ), normal on day 10, again high on day 15-25 ( $p < 0.002$ ), again normal on day 30, high on day 40 ( $p < 0.001$ ), again acquired the normal level on day 50, and high on day 60 post-infection ( $p < 0.001$ ).

Maximum footpad swelling was observed on day 25 post-infection. However, since maximum caecal score was observed on day 20 post-infection, it indicated that the mice developed the DTH response in late course of the disease. On day 60 post-infection, low caecal score was observed, but the DTH response was high. This suggests the persistent nature of the DTH response (2). The cyclic suppression, as observed in our study, resembles the reported cyclic MIF production, either in hamsters or in guinea pigs, inoculated intrahepatically

with *E. histolytica* trophozoites; MIF production reportedly increased gradually in response to specific antigen during infection, but it also decreased at some stage (19-21). In contrast to our study, direct skin tests of *E. histolytica*-infected guinea pigs inoculated intrahepatically showed a negative response at all days tested (4, 8, and 12 days) at all dose levels of the antigen (21). However, consistent to our finding, Gold (5) reported maximum footpad swelling after 24 hours of challenge with *E. histolytica* in immunized animals and also observed a persistent DTH response. It is reported that human patients with amoebic liver abscess (ALA) showed a diminished CMI response to amoebic antigens when assayed by skin test for DTH and MIF production. However, the test became positive when these patients were tested again 10 days after they had been cured and discharged from the hospital (9). In a similar experimental system, we have previously observed that *E. histolytica* infection induced a cyclic depression on DNA synthesis when spleen lymphocytes were stimulated with concanavalin A, pokeweed mitogen, or amoebic antigen (14).

Inflammatory responses to *E. histolytica* have been demonstrated in acute intestinal amoebiasis (22), precluding the possible participation of non-immunologic mechanisms (23). It is reasonable to assume that the non-specific inflammatory response constitutes the first barrier against amoebic infection (5). The finding of the studies conducted by Stern *et al.* (24) and Ghadrian and Kongshavn (25) that silica treatment enhances the susceptibility of mice to *E. histolytica* infections indeed supports this point of view. It is stated that hepatic amoebiasis specifically depresses CMI, as expressed by negative skin reaction and MIF (26). Nonetheless, Kretschmer (27) has reported normal results relating to CMI in invasive amoebiasis; this discrepancy could be due to important stage differences. In our study, we intended to clarify the DTH reactions of mice to antigens on a time-sequence basis. The exact time of exposure can be determined in experimental animals, whereas human studies are not initiated until symptoms appear. Of course, other factors, such as natural variation in hosts, human and animals, and methodological differences, may also help reconcile these results.

SRBC was selected as the heterologous antigen to further investigate the cell-mediated immunity in *E. histolytica*-infected mice. The results showed that the non-infected control and the *E. histolytica*-infected mice were able to exhibit a footpad inflammation to this antigen. Thus, the capacity of mice to maintain their responses to SRBC, but not to *E. histolytica* antigens, indicates that the immunodepression presented by these animals is antigen-specific.

The suppressor effect of *E. histolytica* extract is evident on the afferent limb of the immune response in

hamsters. Nevertheless, this effect has not been observed in mice that have been immunized with sheep erythrocytes (28). It may be speculated that the sustained, exhausting, restricted or polyclonal T-cell activation responses by amoebic antigens (29) can lead from over stimulation to depression of the host cellular immune response. The soluble amoebic antigens may transiently act as suppressors of CMI, permitting the parasite to move into tissues.

The cyclic cell-mediated immune response in terms of DTH as observed in the present study was also reported by other investigators either with *Paracoccidioides brasiliensis* or with *Histoplasma capsulatum* (4,30,31). This phenomenon has been ascribed to immunoregulatory mechanisms associated with T dependent-specific immunodepression, antibody production or by the presence of circulating immune complexes (30,31).

In summary, we observed that the intestinally *E. histolytica*-infected mice developed an evident and persistent DTH response. In spite of the fact that mice serve as test animals in intestinal amoebiasis, very few reports on their immunological status are available. The present work contributes to the characterization of this experimental model.

#### REFERENCES

- Walsh JA. Prevalence of *Entamoeba histolytica* infection. In: Ravdin JI, editor. Amebiasis: human infection by *Entamoeba histolytica*. New York: Wiley, 1988:93-105.
- Ortiz-Ortiz L, Ruiz B, Gonzalez A. Cellular immune responses. In: Kretschmer RR, editor. Amebiasis: infection and disease by *Entamoeba histolytica*. Boca Raton: CRC Press, 1990:77-90.
- Ratcliffe EC, Wilson RA. The magnitude and kinetics of delayed-type hypersensitivity responses in mice vaccinated with irradiated cercariae of *Schistosoma mansoni*. *Parasitology* 1991;103:65-75.
- Fazioli R dos A, Singer-Vermees LM, Kashino SS, Burger E, de Franco MF, Moscardi-Bacchi M, Calich G. Delayed-type hypersensitivity response in an isogenic murine model of paracoccidioidomycosis. *Mycopathologia* 1994;126:137-46.
- Gold D. Delayed-type hypersensitivity to *Entamoeba histolytica* in mice and hamsters: a comparison. *Parasitol Res* 1989;75:335-42.
- Maddison SE, Kagan IG, Elsdon-Dew R. Comparison of intradermal and serologic tests for the diagnosis of amoebiasis. *Am J Trop Med Hyg* 1968;17:540-7.
- Kretschmer RR, Sepulveda B, Almazan A, Gamboa F. Intradermal reactions to an antigen (histolyticin) obtained from axenically cultivated *Entamoeba histolytica*. *Trop Geogr Med* 1972;24:275-81.
- Savanat T, Bunnag D, Chongsuphajaisiddhi T, Viriyanon P. Skin test for amoebiasis: an appraisal. *Am J Trop Med Hyg* 1973;22:168-73.
- Ortiz-Ortiz L, Zamacona G, Sepulveda B, Capin NR. Cell mediated immunity in patients with amoebic abscess of the liver. *Clin Immunol Immunopathol* 1975;4:127-34.
- Landa L, Capin R, Guerrero M. Studies on cellular immunity in invasive amoebiasis. In: Sepulveda B, Diamond LS, editors. Amebiasis; proceedings of the International Conference on Amebiasis, Mexico City, 1976. Mexico City: Instituto Mexicano del Seguro Social, 1976:661-67.
- Sher A, Ahmad S, Muller-Berat CN. Cell mediated immune responses in experimental amoebiasis. *Arch Invest Med (Mex)* 1980;11:201-13.
- Ghosh PK, Mancilla R, Ortiz-Ortiz L. Intestinal amoebiasis: histopathologic features in experimentally infected mice. *Arch Med Res* 1994;25:297-302.
- Diamond LS, Harlow DR, Cunnick CC. A new medium for the axenic cultivation of *Entamoeba histolytica* and other *Entamoeba*. *Trans R Soc Trop Med Hyg* 1978;72:431-2.
- Ghosh PK, Castellanos-Barba C, Ortiz-Ortiz L. Intestinal amoebiasis: cyclic suppression of the immune response. *Parasitol Res* 1995;81:475-80.
- Bradford MM. A rapid and sensitive method for the quantitation of microgram quantities of protein utilizing the principle of protein-dye binding. *Anal Biochem* 1976;72:248-54.
- Robinson GL. The laboratory diagnosis of human parasitic amoebae. *Trans R Soc Trop Med Hyg* 1968;62:285-94.
- Neal RA. Some observations on the variation of virulence and response to chemotherapy of strains of *Entamoeba histolytica* in rats. *Trans R Soc Trop Med Hyg* 1951;44:439-52.
- Gridley MF. A stain for *Entamoeba histolytica* in tissue sections. *Am J Clin Pathol* 1954;24:243-4.
- Ortiz-Ortiz L, Garmilla C, Tanimoko-Weki M, Zamacona-Ravelo G. [Cellular hypersensitivity in amoebiasis. I. Reaction in hamsters inoculated with *E. histolytica*]. *Arch Invest Med* 1973;4:141-6.
- Gold D, Norman LG, Meddison SE, Kagan IG. Immunologic studies on hamsters infected with *Entamoeba histolytica*. *J Parasitol* 1978;64:866-73.
- Bray RS, Harris WG. Cellular immune responses to amoebic liver abscess in the guinea-pig. *Clin Exp Immunol* 1977;29:147-51.
- Prathap K, Gilman R. The histopathology of acute intestinal amoebiasis: a rectal biopsy study. *Am J Pathol* 1970;60:229-45.
- Gold D, Auli H, Keisari Y. Comparative inflammatory reactions in mice and hamsters to *Entamoeba histolytica*. *Parasite Immunol* 1987;9:145-9.
- Stern JJ, Graybill JR, Drutz DJ. Murine amoebiasis: the role of the macrophage in host defense. *Am J Trop Med Hyg* 1984;33:372-80.

25. Ghadirian E, Kongshavn PAL. Effect of silica on resistance of mice to *Entamoeba histolytica* infection. *Infect Immun* 1984;45:399-402.
26. Sepulveda B. Immunology of amebiasis. In: Sepulveda B, Diamond LS, editors. Amebiasis; proceedings of the International Conference on Amebiasis, Mexico City, 1976. Mexico City: Instituto Mexicano del Seguro Social, 1976:668-702.
27. Kretschmer RR. Immunology of amebiasis. In: Martinez-Palomo A, editor. Amebiasis: human parasitic diseases, v.2. Amsterdam: Elsevier, 1986:95-167.
28. Carvajal R, Ruiz B, Barjan E. Immunosuppressive effect of *Entamoeba histolytica* extract on hamsters. *Z Parasitenkd* 1983;69:183-9.
29. Diamantstein T, Klos M, Gold D, Hahn H. Interaction between *Entamoeba histolytica* and the immune system. I. Mitogenicity of *Entamoeba histolytica* extracts for human peripheral T lymphocytes. *J Immunol* 1981;126:2084-6.
30. Moscardi M, Franco MF. [Experimental paracoccidiodomycosis in mice. I. Immunopathological aspects of intraperitoneal infection]. *Rev Inst Med Trop Sao Paulo* 1980;22:286-93.
31. Taylor ML, Diaz S, Gonzalez PA, Sosa AC, Toriello C. Relationship between pathogenesis and immune regulation mechanisms in histoplasmosis: a hypothetical approach. *Rev Infect Dis* 1984;6:775-82.